

## Keratoconus: A Progressive Eye Disease

Ravi Kant Kumar<sup>1</sup> and Sugato Banerjee<sup>\*2</sup>

<sup>1</sup>Department of Pharmaceutical Sciences and Technology, Birla Institute of Technology, Mesra, Ranchi, India

<sup>2</sup>Department of Pharmacology and Toxicology, National Institute of Pharmaceutical Education and Research, Kolkata, India

### Abstract

Keratoconus a progressive eye disease associated with corneal thinning and bulging resulting in blurred vision nearsightedness and irregular astigmatism. It is less common than other eye diseases like macular degeneration, cataract, glaucoma or diabetic retinopathy and hence often goes undiagnosed and neglected. However, its incidence is on the rise in tropical countries like India and hence warrants renewed interest among ophthalmologists, optometrists and ophthalmology researchers. The following review summarizes the current knowledge on the etiology, epidemiology, pathogenesis and therapeutic interventions for keratoconus.

\*mail id for correspondence: banerjeesugato1@gmail.com

Received on 22 August 2020; Revised on 13 September 2020; Accepted on 18 September 2020

PHARMAWAVE 2020; 13:03-07.

**Keywords:** Cornea, contact lens, corneal cross linker, eye, ophthalmological disorder

### Introduction

Keratoconus is a progressive eye disease. In this disease the normal cornea starts thinning and start bulging in a shape as of cone [1]. The cone shaped cornea interferes with the light that enters into the way of light sensitive retina, causing blurred vision [2]. It is characterized by irregular astigmatism, high order aberrations and corneal scarring. This progressive disease can occur in one or both eyes, but it mostly affects both eyes, from teen and early 20s (50%) of cases [3]. As this disease cause irregularity in the shape of cornea which leads to nearsightedness and irregular astigmatism. This creates extra problem in distortion and blurring in vision [4]. Keratoconus has been known since the early days of ophthalmology. The term keratoconus was established later on, originally there were various name such as hyperkeratosis or conically formed cornea [5]. The main symptoms that we can find in a person suffering from keratoconus are blurry vision, near sightedness, light sensitivity, itching in the eyes etc. [6]. At the initial stage of the keratoconus the condition cannot be detected by the normal eye check up, so it can't be typically corrected by using power glasses or by soft lens [7]. As the disease worsens the cornea get bulged out due to which vision gets blurred and typically correction methods like glasses and soft lens are not helpful [8]. In most of the people this disease gets fixed after a certain age without severe vision problem [9]. Keratoconus is becoming much more common than in the past. Previously the ratio was 1 in 2000 but now it is 1 in 500 [10]. Prevalence of keratoconus has been reported to be 4.5-7.5 times higher in asian population compared to the white population [11]. It is also lower in the cold northern countries such as Finland, Denmark, Russia where as the % of keratoconus is greater in tropical and subtropical

areas including India [12]. In this review we discuss the current understanding of etiology, pathogenesis and potential interventions for keratoconus.

### **Aetiology of Keratoconus**

The most common risk factor for the keratoconus is the eye rubbing [13]. The continuous rubbing of the eyes at the early age due to eye irritation leads to the risk for developing KC [14]. Eye rubbing and patient family history of KC are the major risk factor known to predict the eventual development of KC [15]. A study also showed that unnecessary use of contact lenses and people with asthma, retinitis pigmentosa, eczema has much faster rate in development of Keratoconus [16, 17]. Diabetes, allergic disorder, collagen abnormality and dipressions have been implicated as minor risk factors for the disease [18, 19]. Thus, like many disorders the development of keratoconus involves both environmental and genetics factors, where the former may make the susceptible person more vulnerable.

### **Pathophysiology of Keratoconus**

Collagens are the fibers of protein which help the cornea to hold it in its place and keep it from bulging out [20]. When these collagen fibers become weak, they cannot hold the cornea in its position which leads to bulging of the cornea to form a cone shaped structure. Earlier theories of pathogenesis include epithelial abnormality (blebbing and degeneration) and release of proteolytic enzymes responsible for the degradation of the stromal collagen. Other structural changes include breaks in the Bowman's layer and thinning of the stroma. Compared to normal cornea keratoconus tissue has increased expression of decorin and keratocan. There are fewer keratin sulfate and lower collagen content in KC tissue. However, there is little change in either distribution of different types of collagen or their cross linking arrangement in the stromal layer of cornea. Proteomic analysis of tear samples from KC patients has shown changes in expression of cytokines and apoptotic markers which correlates with scarring of the tissue. These studies also showed reduction in the levels of proteins involved in growth, proliferation and migration along with alteration in extracellular matrix proteoglycans and increase in markers for oxidative stress. While structural studies have proposed that altered corneal structure in KC is primarily due to altered matrix proteins and keratinocytes while increased proteolysis causing untying of lamella along its length. The above factors result in redistribution of lamella far from the pinnacle of the cornea and leads to reduction of inter lamellar adhesion and interlacing.

### **Genes involved with Keratoconus**

KC pathogenesis has a major genetic component which is highly diverse. Out of 17 genetic loci potentially involved in the development of KC only 5q21,75,76 5q3275,77 and 14q11 have been independently implicated. Among these loci again genes leading to KC is yet to be identified. A pathogenic variant of DOCK9 gene has been identified and linked to KC pathogenesis. Genome wide association studies (GWAS) showed single-nucleotide polymorphism (SNP) near RAB3GAP1 to be associated with KC. GWAS studies on loci associated with central corneal thickness (CTT) one of the risk factor for developing KC have shown six SNPs in or near the following genes; FOXO1, FNDC3B, RXRA-COL5A1, MPDZ-NF1B, COL5A1, and ZNF469. Overall, gene expression studies identified altered expression of genes involved in the cytoskeletal arrangement, development of extracellular matrix and cell-matrix interaction.

An increase in KRT6 has been reported while decrease in alcohol dehydrogenase (class 1) beta polypeptide (ADH1B) in keratinocytes in culture. Cultured stromal fibroblasts showed differential expression of metalloproteinases (TIMP 1 and 3) and BMP4 while AQP5 expression was downregulated in corneal epithelium in KC. For further details please refer to Davidson et al 2014[21].

### **Diagnosis of Keratoconus**

Currently keratoconus and other corneal ectatic diseases are diagnosed by studying the corneal topography. Placido disc systems, scanning slit devices (Orbscan, Bausch & Lomb) and Scheimpflug imaging (Pentacam, Oculus) are being used to determine any change in corneal curvature. Systems measuring the elevation in corneal topography are widely used in the diagnosis of keratoconus. Cross-sectional Optical coherence popular tool for the diagnosis of early keratoconus [22].

### **Preventive measures and physical therapies for KC Physical Therapies**

Weight reduction, physical exercise, eye exercise or even simply remaining healthy may protect against KC.

Swaying is a simple eye exercise that helps in reinforcing the command over the corneal muscles of the eyes. In disease like KC people suffers from the symptoms like distorted and blurred vision. This physical therapy helps in controlling where the eyes go, and strengthens the muscles around the eye. Keeping the feet and shoulder way apart an object is chosen in a distance. Then the person sways from one side the other side with a constant focus on the particular object [23].

The American Optometric Association recommends activities like badminton and team sports which reinforces the corneal muscles by improving the overall visual sharpness and protect against the development of KC [23].

### **Preventive measures**

Managing allergies and taking nutritional supplements can help manage the condition. If eyes are itchy due to allergies, antihistamine may help along with avoiding the allergens. Sometimes skin and food allergies may also cause eye inflammation and could be related to KC. Diet low in calcium and other nutrients might contribute to or worsen KC. Thus drinking 2 to 3 glasses of milk per day is recommended to meet the daily calcium requirement. Other sources of calcium include cheese, yogurt, spinach, kale, and soybeans or 500-1000 mg calcium is usually recommended. A daily dose of 2,000 to 4,000 IU of vitamin D might help slow the progression of KC. In case of persistently itchy eyes, saline eye drops or non-medicated artificial tears are recommended to avoid rubbing of eyes thus preventing KC [24].

### **Current therapies for KC Customize soft contact lenses:**

The initial step for the treatment of the KC is using of customized lenses specially made to correct initial abnormalities of KC. They are designed after measuring of the person's cornea (s). One of the primary complications for keratoconus eye being higher-order aberrations (HOAs) could be rectified through customized contact lenses. Rigid corneal lenses and rigid scleral lenses have been shown to reduce the magnitude of HOAs in keratoconic eye while non-customized soft contact lenses have been shown to be less effective. While others have proposed aberrations in the posterior cornea surface to be responsible for HOAs in keratoconus [25].

### **ICRS or Intrastromal corneal ring sections:**

They are also called intacs which are arc-shaped synthetic implants in the cornea. They are implanted into a tunnel created on the outer part of the cornea by using laser or another surgical appliance. ICRS are the implantation to reshape the cornea by making them more symmetric and also helps in flattening the arch of the cornea. Patients in the moderate and severe stage of keratoconus without corneal scarring having difficulty with contact lenses are the best suited for ICRS. Individuals with  $K_{max} > 70$  D, corneal scarring and opacity, or hydropsis are not recommended for ICRS. Among various commercially available ring systems Intacs and Ferrara rings are most widely used for the management of the condition. Positioning and implantation depth of the ring can define its effectiveness since improper positioning can lead to

overcorrection or under-correction while implantation at 60-80% of the corneal thickness has been found to be most effective [26]. One of the primary disadvantages of ICRS is that they fail to prevent the progression of KC. In few cases of KC doctors combine the therapy of ICRS implantation with crosslinking of the cornea as a method of treatment. However, little is known about the advantages of this combination therapy [27].

### **Corneal Cross linking (CXL)**

It is one of the best available treatments for KC approved by the U.S. Food and Drug Administration (USFDA) since 2016. Corneal Cross linking is a non-surgical process which strengthens the weak corneal structure by allowing bond formation between the collagen fibers in the stroma. CXL can increase corneal rigidity by more than 3 times while reducing corneal ectasia. The main advantage of the CXL is that it stops or slows the progression of KC. However, CXL cannot reverse KC associated changes thus the procedure is usually recommended for early KC cases with a clear cornea with a minimum thickness of 400 microns. In this procedure a beam of ultraviolet light (370 nm) is applied to remove the upper layer of the cornea. This process is done in conjunction with administration of vitamin B2 (riboflavin) containing ophthalmic preparation. CXL in combination with photoreactive keratectomy or laser assisted in situ keratomileusis (LASIK) prove to be more effective [26, 28].

### **Corneal Transplant**

It is considered as a last resort. It became the most important and the method of choice for severest of cases when all the previous methods have failed. In the process of corneal transplant, the tissue used is harvested from an organ donor. Corneas are removed from the donor eyes. The process of penetrating keratoplasty is a common transplant procedure in which there are high chances of excellent correctable vision. For this process a surgical cookie-cutter is used for the removal of the complete thickness of the cornea (from epithelium layer to endothelium layer). The affected cornea is replaced with a new cornea of similar size. Patients are prescribed few ophthalmic solutions for a long period of time to prevent rejection of the transplanted cornea. With proper care, transplants can usually last for decades. Currently the removal of the affected cornea with donor cornea is done with the help of Femtosecond Laser instead of a trephine and this procedure is known as Femtosecond-Laser Enabled Keratoplasty (FLEK). The Laser assisted surgery heals the wound faster. This also helps in stronger collagen bond formation in the cornea, which results in better vision outcomes.

A new technique which is known as Deep Anterior Lamellar Keratoplasty (DALK) is an alternate to corneal transplant. The process of the (DALK) is increasingly sensitive transplant, in which the top or the external layers of the affected cornea is supplanted, yet some parts, like Descemet's film and endothelium are left intact. The process of Deep Anterior Lamellar Keratoplasty is less invasive compared to cornea transplant with faster recovery time and little chance of the graft rejection [29].

Keratoplasty, approved by USFDA in 2002 is a method which can be used for the correction of low and moderate hyperopia (+0.75 to +3.00 D) and astigmatism less than 0.75 D. This is an effective method even for thin corneas. In this method radio wave (350 HZ) is applied to the corneal stroma at various points (8-30) which increases the tissue temperature by up to 65°C causing collagen shrinkage, corneal steepening leading to corneal remodeling and eventual correction of refractive errors. However, it not very effective for keratoconus eye with high astigmatism and also cannot prevent the progression of the disease and hence sometimes combined with CXL [30].

### **Pharmacological Interventions**

They are relatively few against KC. Many clinical trials are in progress, while ophthalmic solutions are also being used to reduce eye pressure (anti-glaucoma) which may reduce the risk of developing KC. FDA-approved medication to treat the progression of KC is riboflavin 5'-phosphate ophthalmic solution

as photoenhancer. Avedro's Photrexa Viscous (riboflavin 5'- phosphate in 20% dextran ophthalmic arrangement), Photrexa (riboflavin 5'- phosphate ophthalmic arrangement) has been affirmed by the USFDA as the solitary epithelium corneal cross-linker against dynamic KC [31]. Antihistamines mostly mast cell stabilizers, NSAIDs and sometimes steroids may be used to prevent ocular allergies like pruritis and giant papillary conjunctivitis reducing rubbing of eyes, a major risk factor for KC. The various therapeutic approaches against KC has been summarized in Figure 1

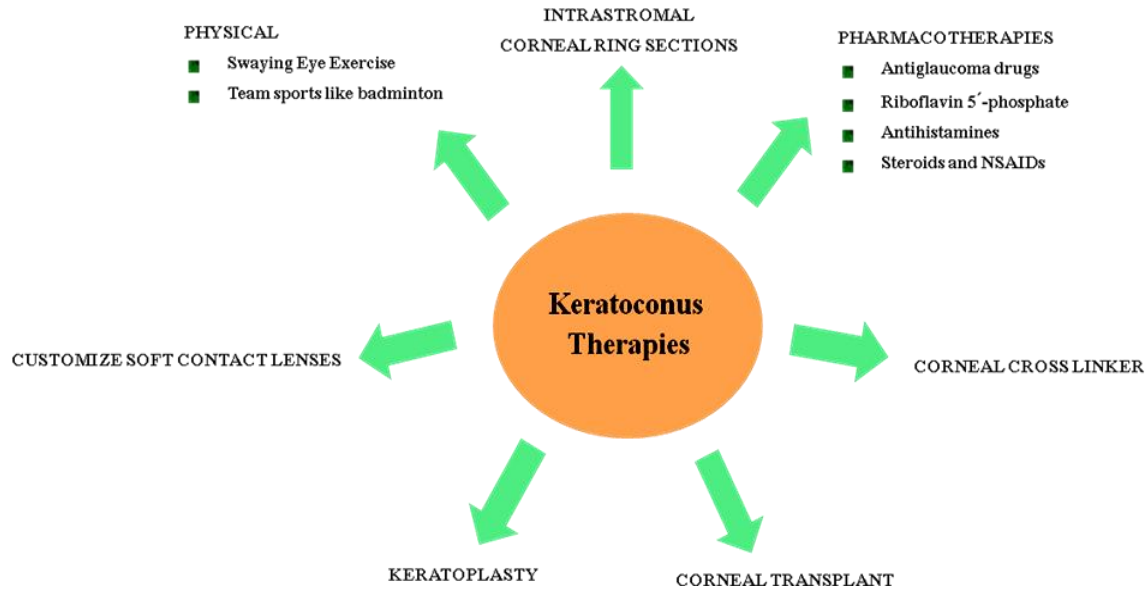


Figure 1: Different therapeutic strategies against keratoconus

### Potential Future Therapies of KC

Researchers are trying to develop creative tissue engineering which with use of an ophthalmic solution which contain very low amount of a combination steroid and growth factor to reshape and settle the cornea in a controlled way. In KC corneal tissue undergoes increased oxidative stress which eventually leads to the damage. Animal models have shown a therapeutic effect of Vitamin C (ascorbate) in corneal wound healing. To this date, the role of systemic antioxidant supplementation in KC patients is yet to be evaluated. The role of antioxidant supplementation like Vitamins A, C and E—in delaying the progression of KC is also been evaluated. IVMED-80 a copper-based formulation is the first eye drop formulated for the treatment of KC without any surgical requirement [32]. Preclinical studies using IVMED-80 resulted in central flattening and increased stiffening of the cornea in rabbits while studies of the ophthalmic formulation on the human corpse resulted in increased lysyl oxidase (LOX) activity, reduced in KC and increased stiffness of human keratoconic corneas [33].

### Summary

KC is a progressive eye disease where the cornea thins and becomes conical in shape. This eventually results in visual impairment like blurred vision near-sightedness and astigmatism. It is a relatively rare eye disease with few pharmacological therapies. However, its incidence is on the rise especially in tropical and subtropical countries and warrants large scale preclinical research and clinical trial initiatives targeted towards early diagnosis and therapy for the disease.

**Acknowledgement:** We would like to acknowledge Department of Pharmaceutical Sciences and Technology, Birla Institute of Technology for their infrastructural support.

### References

1. Krachmer JH, Feder RS, Belin MW. Keratoconus and related noninflammatory corneal thinning disorders. *Surv Ophthalmol* 1984; 28(4): 293–322.
2. Rabinowitz YS. Keratoconus. *Surv Ophthalmol* 1998; 42(4): 297–319.
3. Hill AB. The Environment and Disease: Association or Causation? *Proc R Soc Med* 1965; 58: 295–300.
4. Eichler EE, Flint J, Gibson G, Kong A, Leal SM, Moore JH et al. Missing heritability and strategies for finding the underlying causes of complex disease. *Nat Rev Genet* 2010; 11(6): 446–450.
5. Tsubota K, Mashima Y, Murata H, Sato N, Ogata T. Corneal epithelium in keratoconus. *Cornea* 1995; 14(1): 77–83.
6. Sawaguchi S, Fukuchi T, Abe H, Kaiya T, Sugar J, Yue BY. Three dimensional electron microscopic study of keratoconus. *Arch Ophthalmol* 1998; 116: 62–98.
7. Sturbaum CW, Peiffer RL Jr. Pathology of corneal endothelium in keratoconus. *Ophthalmologica* 1993; 206(4): 192–208.
8. Critchfield J, Caladra A, Nesburn A, Kenney M, Keratoconus. I. Biomechanical studies of normal and keratoconus cornea. *Exp Eye Res* 1988; 46: 953–963.
9. Buddecke E, Wollensak J. Acid mucopolysaccharide and glycoprotein in the human cornea in relation to age and keratoconus. *Albrecht von Graefes Arch Klin Exp Ophthalmol* 1966; 172: 105–120.
10. Joseph R, Srivastava OP, Pfister RR. Differential epithelial and stromal protein profiles in keratoconus and normal human corneas. *Exp Eye Res* 2011; 92(4): 282–298.
11. Fullwood NJ, Tuft SJ, Malik NS, Meek KM, Ridgway AEA, Harrison RJ. Synchrotron x-ray diffraction studies of keratoconus corneal stroma. *Invest Ophthalmol Vis Sci* 1992; 33(5): 1734–1741.
12. Kenney M, Chwa M, Oprobek AJ, Brown DJ. Increased gelatinolytic activity in keratoconus cultures. A correlation to an altered matrix metalloproteinase-2/tissue inhibitor of metalloproteinase ratio. *Cornea* 1994; 13(2): 114–124.
13. Bron AJ. Keratoconus. *Cornea* 1988; 7(3): 163–169.
14. Morshige N, Wahlert A, Kenney M, Brown D, Kawamoto K, Chikama T et al. Second harmonic imaging microscopy of normal and keratoconus cornea. *Invest Ophthalmol Vis Sci* 2007; 48(3): 1087–1094.
15. Abahussin M, Hayes S, Knox Cartwright N, Kamma-Lorger C, Khan Y, Marshall J et al. 3D collagen orientation study in human cornea using x-ray diffraction and femtosecond laser technology. *Invest Ophthalmol Vis Sci* 2009; 50(11): 5159–5164.
16. Sherwin T, Brookes NH, Loh IP, Poole CA, Clover GM. Cellular incursion into Bowman's membrane in the peripheral cone of the keratoconic cornea. *Exp Eye Res* 2002; 74(4): 473–482.
17. Zhou LL, Sawaguchi S, Twining SS, Sugar J, Feder RS, Yue BY. Expression of degradative enzymes and protease inhibitors in corneas with keratoconus. *Invest Ophthalmol Vis Sci* 1998; 39: 1117–1124.
18. Funderburgh JL, Hevelone ND, Roth MR, Funderburgh ML, Rodrigues M, Nirankari VS et al. Decorin and biglycan of normal and pathological human corneas. *Invest Ophthalmol Vis Sci* 1998; 39(10): 1957–1964.
19. Meek K, Blamires T, Elliot G, Gyi TJ, Nave C. The organisation of collagen fibrils in the human corneal stroma: a synchrotron x-ray diffraction study. *Curr Eye Res* 1987; 6(7): 841–846.
20. Polack FM. Contributions of electron microscopy to the study of corneal pathology. *Surv Ophthalmol* 1976; 20: 375–414.
21. Davidson AE, Hayes S, Hardcastle AJ, Tuft SJ. The pathogenesis of keratoconus. *Eye* 2014;28(2):189.

22. Yip H, Chan E. Optical coherence tomography imaging in keratoconus. *Clin Exp Optom.* 2019 ;102(3):218-223.
23. Exploring exercise and keratoconus. <https://keratoconusinserts.com/exploring-exercise-and-keratoconus>. (Accessed on 21/08/2020)
24. Early prevention of keratoconus can save your vision. don't fall off the keratoconus cliff! <https://keratoconusinserts.com/early-prevention-of-keratoconus-can-save-your-vision>. (Accessed on 21/08/2020)
25. Jinabhai AN Customized aberration-controlling correction for keratoconic patients using contact lenses *Clin Exp Optom.* 2020; 103(1) 31-43
26. Mohammadpour M, Heidari Z, Hashemi H. Updates on Managements for Keratoconus. *J Curr Ophthalmol.* 2017; 30(2):110-124
27. How is keratoconus treated. [https://www.nkcf.org/how-is-keratoconus-treated/Keratoconus causes, symptoms and ten treatment options](https://www.nkcf.org/how-is-keratoconus-treated/Keratoconus-causes-symptoms-and-ten-treatment-options). <https://www.allaboutvision.com/conditions /keratoconus.htm> (Accessed on 21/08/2020)
28. Alternative treatment options for keratoconus patients. <http://amkca.org/2012/01/>. (Accessed on 21/08/2020)
29. Alio JL, Claramonte PJ, Caliz A, Ramzy MI. Corneal modeling of keratoconus by conductive keratoplasty. *J Cataract Refract Surg.* 2005; 31(1):190-197.
30. Dudakova L, Sasaki T, Liskova P, Palos M, Jirsova K. The presence of lysyl oxidase-like enzymes in human control and keratoconic corneas. *Histol Histopathol.* 2016; 31(1):63-71.
31. Solo eye drop treatment in development of keratoconus. <https://crstoday.com/articles/2018-feb/solo-eye-drop-treatment-in-development-for-keratoconus>. (Accessed on 21/08/2020)
32. Pahuja N, Kumar NR, Shroff R, et al. Differential molecular expression of extracellular matrix and inflammatory genes at the corneal cone apex drives focal weakening in keratoconus. *Invest Ophthalmol Vis Sci.* 2016;57(13):5372-5382.